



Mark Craig BVSc CertSAD MRCVS

Mark Craig qualified from Liverpool University in 1985. After 5 years in general veterinary practice, Mark spent three and a quarter years as resident in dermatology at the Royal Veterinary College, where he gained his certificate in small animal dermatology. Since leaving the college in 1993, he has built up **Re-Fur-All Referrals**, a veterinary dermatology referral service in the South of England and the West Midlands.

Mark has written and lectured extensively on animal skin diseases, translated dermatology articles and text books from French to English, and presented papers at national and international dermatology congresses.

Re-Fur-All Referrals, 31 Porchester Road, Newbury, Berkshire, RG14 7QH

Tel: 01635 35600

E-mail: mark@markcraig.co.uk



For Dermatology Referrals in your area: vetindex.co.uk/derm

For Lab Tests and Equipment: vetindex.co.uk/Lab

Market your referrals in VetIndex!
For further information call us on 01225 445561 or e-mail: vetindex@me.com

Diagnosis and management of pemphigus foliaceus in dogs

Pemphigus foliaceus (PF) is one of a group of uncommon auto-immune diseases known as the pemphigus complex. Many studies have been conducted to determine the major antigen(s) for PF in the dog but so far without success. Drugs, allergic skin disease, and environmental factors are believed to be triggers. Canine PF is a pustular, crusting dermatosis, principal differentials for which include superficial bacterial folliculitis, demodicosis, dermatophytosis and other pemphigus conditions. Diagnosis is based on clinical history and signs, cytology and skin biopsies. The treatment of choice is immune suppression and the prognosis is variable.

Key words: Pemphigus, crusting, canine, auto-immune, dog

Introduction

Pemphigus foliaceus (PF) is one of a group of uncommon auto-immune diseases known as the pemphigus complex (Figures 1-4). The condition was first reported in the dog in 1977 (Halliwell and Goldschmidt 1977) and is now considered the most frequently occurring auto-immune dermatosis in dogs (Vaughan *et al.* 2010). The incidence of PF in the general canine population is unknown but was reported to be 2% of referred cases in one dermatology practice (Rosenkrantz 2004).

Pathogenesis

The pathogenesis of human PF involves the production of auto-antibodies against a target protein, desmoglein (dsg) 1, found in desmosomes, the adhesion molecules of keratinocytes (Miller *et al.* 2013¹). Many studies have been conducted to determine the major antigen(s) for PF in the dog but so far without success (Olivry 2006). Some studies (Suter 1993; Iwasaki *et al.* 1997) have suggested that, as in human PF, dsg1 is the target auto-antigen in canine PF, but it is currently thought that dsg1 is only a minor auto-antigen for canine PF (Olivry 2006). Canine PF appears to be clinically, histologically and immunologically heterogeneous (Olivry 2006).

Triggers

Drugs

In humans, drugs are a recognised trigger for pemphigus foliaceus (Wolf *et al.* 1991). Drug eruptions are notoriously hard to prove but there have also been a number of reports describing an association between drugs and PF-like signs in the dog. PF-like cutaneous adverse drug eruptions following application of metaflumizone and amitraz (Promeris Duo, Fort Dodge) (Oberkirchner *et al.* 2011); fipronil, amitraz and S-methoprene

(Certifact, Merial) (Bizikova *et al.* 2014); and dinotefuran, prapoxifen and permethrin (Vectra 3D, Ceva Animal Health) (Bizikova *et al.* 2015) have been reported. In other reports, reactions to trimethoprim-sulphonamides, cephalixin and oxacillin have been proposed (Medleau *et al.* 1990; White *et al.* 2002).

Allergic skin disease

An association with allergic skin disease has also been proposed. 11.6% of dogs diagnosed with PF had a diagnosis of concurrent atopic dermatitis (Gomez *et al.* 2004). In another study, 15 out of 40 dogs (37.5%) diagnosed with PF had a history consistent with allergic dermatitis, with flea allergy documented in 9 (60%) of these dogs (Vaughan *et al.* 2010). Definitive proof for such an association is hard to establish. A drug reaction, either induced or triggered, cannot be ruled out given that these dogs had all been treated many times with different drugs.

Environmental factors

The role of environmental factors in triggering flares of canine PF has been reviewed (Olivry 2006). Lesional scores of PF worsened in the summer in 10 out of 12 dogs, and improved in the winter (Iwasaki and Yamakita-Yoshida, 2003). Seasonal exacerbation was not, however, found in an epidemiological study involving 66 dogs with PF (Pascal *et al.* 1995). Experimentally, findings from experimental studies using ultraviolet (UV) light radiation suggested that further investigation of UV exacerbation of canine superficial pemphigus was warranted (Iwasaki and Maeda, 1997). Diet has been implicated in human forms of pemphigus (Ruocco *et al.* 1996; Tur and Brenner 1998) particularly in relation to thiols (e.g. in garlic, onion, leek and chive), isothiocyanates (e.g. in mustard, horseradish, turnip, radish,

cabbage, cauliflower and Brussel sprouts), phenols (e.g. in mango, cashews and many food additives), and tannins (e.g. in tea, coffee, and certain fruits including apples, pears and bananas). There have been anecdotal reports of food-induced PF in dogs.

Insect vectors (e.g. black flies), viruses, local heat, and humidity have also been suspected of being predisposing factors in human PF (Lombardi *et al.* 1992) - Table 1.

Table 1. Environmental factors suspected of being predisposing factors or triggers in human PF

- Ultraviolet light
- Insects
- Diet
- Viruses
- Heat and humidity

Signalment

Most cases occur in middle-aged or older dogs but any age can be affected (Vaughan *et al.* 2010). In one review of 37 dogs (Ihrke *et al.* 1985¹), signs presented initially at 5 years or less in 65% of cases. Any breed may be affected but some reports have shown the English Bulldog, Chow Chow, Akita, Dachshund, Cocker Spaniel and Labrador Retriever to be over-represented (Ihrke *et al.* 1985¹; Vaughan *et al.* 2010). No sex predilection has been confirmed but one report showed a significant male bias (Gomez *et al.* 2004).

Clinical signs

The head and face are predisposed, seen in over 80% of cases, and typically the first areas to be affected, especially the dorsal muzzle, planum nasale, peri-ocular skin and ears where lesions are typically bilaterally symmetrical (Figures 5, 6). In the largest case series, lesions were restricted to the face in 15 out of 91 dogs (16%) (Mueller *et al.* 2006). In the same study, footpads were involved in a third of cases, and lesions became generalised in 60 dogs (66%). Crusting was present on the trunk in 58% of dogs with generalised lesions (Figures 7, 8). Occasionally, lesions may be restricted to the footpads (Ihrke *et al.* 1985²)

Pruritus and pain are variable, and systemic signs may include anorexia, pyrexia, depression, weight loss and lymphadenopathy (Olivry 2006). Canine PF is a pustular, crusting dermatosis. The primary lesion may start as a papule, progressing quickly into a pustule. Large pustules are characteristic (Figure 9), and extensive areas of erosions, yellow crusts,

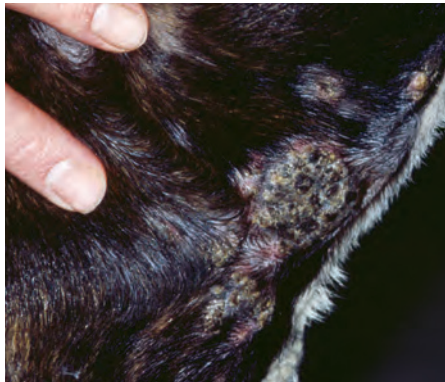


Figure 1: Pustules and crusts on the neck of a 2-year old entire male Staffordshire Bull Terrier with pemphigus foliaceus

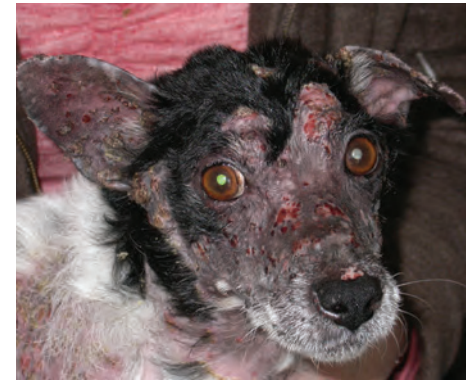

Figure 5: Severe crusting and alopecia on the head of a 10-year old neutered male Jack Russell Terrier with pemphigus foliaceus

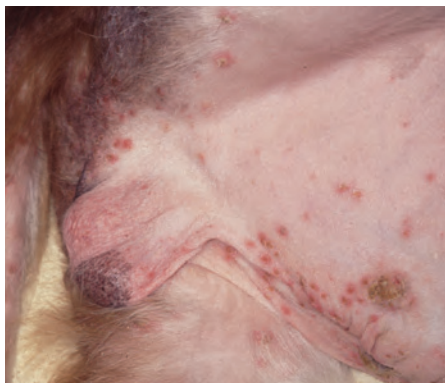

Figure 2: Papules, pustules and crusts on the ventral abdomen, legs, tail and perineal region of an 8-year old entire male Cavalier King Charles spaniel with pemphigus foliaceus

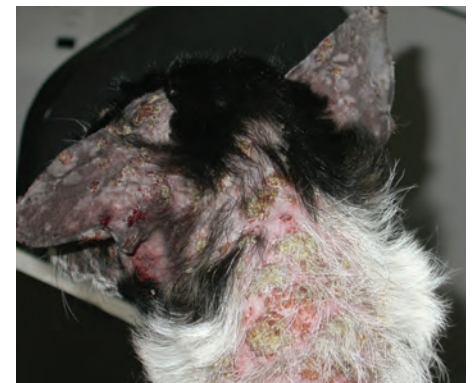

Figure 6: Severe focal crusting and alopecia on the ears and dorsal neck of a 10-year old neutered male Jack Russell terrier with pemphigus foliaceus

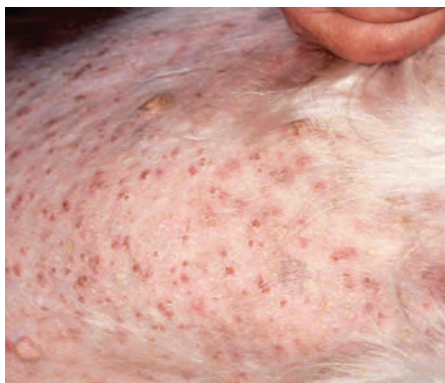

Figure 3: Papules, pustules and crusts on the ventrum of an 8-year old entire male Cavalier King Charles Spaniel with pemphigus foliaceus

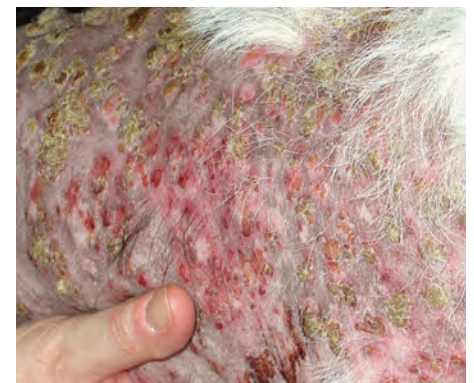

Figure 7: Severe generalised focal crusting and alopecia in a 10-year old neutered male Jack Russell Terrier with pemphigus foliaceus

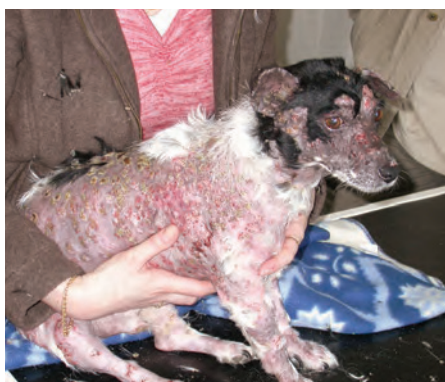

Figure 4: Severe generalised crusting and alopecia in a 10-year old neutered male Jack Russell Terrier with pemphigus foliaceus

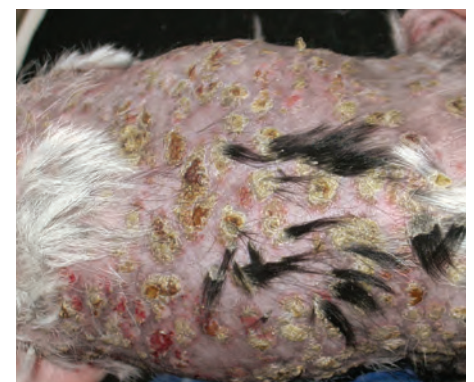

Figure 8: Severe focal crusting and alopecia of the ventral abdomen of a 10-year old neutered male Jack Russell Terrier with pemphigus foliaceus